

Non-destructive Laser for the Retina

By John W. Kitchens, MD



When anti-VEGF injections became available for treatment of age-related macular degeneration, diabetic macular edema, and retinal vein occlusion, some predicted the demise of laser photocoagulation because of the destructive properties of the treatment. Conventional laser photocoagulation, although effective in stopping leakage and reducing macular edema, is destructive to important ocular structures, causing permanent damage and scotomas that will be with the patient for life. Now, however, sub-threshold, sub-visible treatment with photo-thermal stimulating lasers offers the possibility to avoid permanent damage while delivering many of the benefits of conventional laser.

In fact, rather than a decline of laser use, I have experienced a resurgence of grid laser treatments in my practice recently. Increasingly, patients are either recalcitrant to treatment with anti-VEGF agents or simply do not want to undergo monthly or 6-weekly injections to keep their retinas dry. With sub-visible laser treatment, we can offer an alternative to frequent injections. Among the advantages of this modality:

Sub-threshold laser can help reduce treatment burden. This modality can be a helpful option for patients with persistent leakage despite frequent repeated injections, patients with early recurrence of leakage, or those who cannot do or not wish to continue monthly or bimonthly injections.

Sub-threshold laser is repeatable. After performing sub-threshold treatment, the physician can observe to see if the desired effect is achieved. If a partial effect is achieved—say the edema is reduced 50% more than with previous anti-VEGF therapy—the procedure can be safely repeated to try to restimulate the tissue without causing additional atrophy and vision loss. Sub-threshold treatment allows the ophthalmologist to provide patients with the precise amount of photoenergy needed to stimulate cells without destroying tissues in the retina.

As mentioned, the availability of this treatment mode has led to a resurgence in my own use of grid laser. For non-destructive laser treatment as provided by the Endpoint Management software (Topcon Medical Laser Systems), the PASCAL pattern scanning laser is a real plus. Often in patients with diffuse edema, when treatment is applied with sub-threshold micropulse laser, it can be difficult to keep track of the treated area. My preference is to use the grid scanning patterns because they help me keep track of where I have placed the sub-threshold treatments. The grid treatment also helps to ensure adequately spaced spots, and permits a more tightly spaced grid than could be achieved manually with sub-threshold laser. This may ultimately give us better results and better outcomes. ■

John W. Kitchens, MD, is a Partner with Retina Associates of Kentucky in Lexington. He may be reached at jkitchens@gmail.com.

CONTENTS

Combination Treatment Key to Success in Diabetic Macular Edema 2

It's time to rethink what laser therapy means.

By Pravin U. Dugel, MD

Retinal Laser Therapy Below the Threshold of Visible Damage 4

The Endpoint Management algorithm provides reliable titration to allow reproducible tissue effects.

By Daniel Palanker, PhD; and Daniel Lavinsky MD, PhD

Novel Approaches to Laser Therapy to the Macula 6

Photo-thermal stimulation laser treatment offers many advantages over conventional laser.

By Daniel Lavinsky, MD, PhD

Combination Treatment Key to Success in Diabetic Macular Edema

It's time to rethink what laser therapy means.

By Pravin U. Dugel, MD



Laser photocoagulation was the standard care for almost 30 years for diabetic macular edema (DME). The Early Treatment for Diabetic Retinopathy Study (ETDRS) in 1985 showed that laser for clinically significant macular edema was effective.¹ The introduction of anti-VEGF agents, however, has changed our treatment regimens for DME. The findings of the first large clinical trial comparing 0.5 mg ranibizumab plus prompt or deferred laser vs intravitreal 4 mg triamcinolone acetonide plus prompt laser vs sham injection with prompt laser definitively showed the superiority of anti-VEGF with prompt or deferred laser vs laser alone.² It also highlighted the importance of combination therapy for this multifactorial disease.

TREATMENT WITH ANTI-VEGF: A CLOSER LOOK

In the Diabetic Retinopathy Clinical Research Network (DRCR.net) Protocol I, patients were randomized to 1 of 4 treatment groups. Treatment was every 4 weeks up to week 16 of the study. Thereafter, treatment was every 4 weeks if there was continued improvement in macular edema, unless the optical coherence tomography (OCT) showed a completely dry macula. If, after stopping treatment, there was any recurring thickening of the macula, treatment was resumed.

At week 16, approximately 25% of patients in the ranibizumab plus prompt laser arm and 22% in the ranibizumab plus deferred laser arm were deemed “successes,” meaning that they had visual acuity of greater than or equal to 20/20 and OCT thickness of less than 250 μm . In further follow-up, however, approximately 90% of these eyes that were considered successes regressed on OCT and required further treatment.

IMPORTANT CONSIDERATIONS

Protocol I was an important study for all of us who treat patients with DME, and I believe that, when asked, most clinicians will say that they follow the treatment protocol in this study. However, I believe that very few truly understand it. The treatment regimen of Protocol

I was very detailed and complicated and was facilitated by a web-based system that, with real-time feedback from the investigators, would indicate whether treatment was required at a given time, whether that treatment should be intravitreal injection or focal/grid laser photocoagulation, and when the patient should be brought back for follow-up. In fact, in a subsequent paper explaining the rationale for the study design, the authors stated that, “Duplication of the approach used in the DRCR.net randomized clinical trial to treat DME involving the center of the macula with intravitreal ranibizumab may not be practical in clinical practice.”³

Regarding efficacy, it is important to note that the majority of the treatment successes at week 16 had recurring edema after a period of not receiving anti-VEGF injections, suggesting that, even if there is an initial robust response to anti-VEGF therapy, there is often no permanent structural advantage.

Another consideration regarding Protocol I is that the first opportunity to decrease treatment burden—in other words, not to see patients every 4 weeks—was at week 64. Many of our patients with DME are young and still members of the workforce, and few would be, in my experience, willing to commit to visiting my office every 4 weeks for over 1 year. The DRCR.net realized this, and in response, proposed a modified regimen that would be more realistic in a clinical setting. However, this more practical and abbreviated protocol has not been subject to the rigors of a clinical trial. Therefore, it is not known whether the results will mirror those of Protocol I.

Anti-VEGF therapy has, without a doubt, changed the outlook for retina disease. We have learned a good deal of information since the approval of ranibizumab (Lucentis, Genentech) and aflibercept (Eylea, Regeneron) and with off-label use of bevacizumab (Avastin, Genentech). However, these valuable and efficacious drugs are not without side effects: There are consequences associated with the long-term use of anti-VEGF agents, even when injected inside the eye. There were some concerning safety signals found in the CATT⁴ and the IVAN⁵ trials for bevacizumab, as well as for aflibercept in the European Public Assessment Report.⁶ Patients

with comorbid diseases may be particularly vulnerable.⁷

Patients with DME tend to be younger and will likely have to undergo therapy for a longer period of time than those with age-related macular degeneration. Therefore, long-term safety consequences must be considered. These patients also tend to be more vulnerable—they are often being treated for comorbid diseases and tend to be sicker.

As efficacious and valuable as anti-VEGF therapy monotherapy is, it appears to provide no permanent structural advantage, it may not be sustainable, and there may be important safety considerations.

WHAT ABOUT CONVENTIONAL LASER?

There is an important misconception about efficacy that must be addressed regarding conventional laser treatment. Very few patients in the ETDRS study gained 3 lines or more with laser treatment. This finding has to be evaluated in proper perspective. Approximately 40% of patients who were enrolled had visual acuities of 20/40 or better, which means these patients could not improve by 3 or more lines—it was simply mathematically impossible. If one looks specifically at those who had visual acuity worse than 20/40 at enrollment, the majority of those patients improved by 3 lines or more.¹

A legitimate concern regarding laser photocoagulation is that it is destructive, creating scars and scotomas. This is particularly problematic in DME in younger patients because they are more prone to atrophic creep, or slow expansion of laser scars over time. What may have started out as a small burn spreads, sometimes over a period of decades, and can result in large, unintended, visually debilitating scotomas.

The idea that destruction of microaneurysms is necessary with laser photocoagulation has been revised; the wavelengths used with conventional laser are not absorbed by the blood vessels. Its mechanism of action is not the destruction of retinal microaneurysms, but rather the stimulation of the retinal pigment epithelium (RPE). The unintended consequence was the photodestruction of the RPE and the dependent photoreceptor cells. The Holy Grail would be to stimulate the RPE without destroying photoreceptor cells.

PHOTO-THERMAL STIMULATION LASER THERAPY

Endpoint Management (EpM; Topcon Medical Laser Systems) uses photo-thermal stimulation, which selectively stimulates the RPE without the destruction associated with conventional laser photocoagulation. Using EpM, we can precisely reduce the power and specifically affect RPE cells. How to best apply EpM in DME still must be rigorously studied, but I believe that it will be a

The reproducibility of photo-thermal stimulation with EpM allows for successful re-treatment.

valuable addition to our current regimen of anti-VEGF therapy and steroid delivery devices.

Photo-thermal stimulation is an attractive option for many reasons, 3 of which are: (1) it may help to reduce the treatment burden in DME; (2) there are no systemic side effects; and (3) it is effective without causing undue damage to tissue. Additionally, the reproducibility of photo-thermal stimulation with EpM allows successful re-treatment.

HOW MIGHT WE APPLY ENDPOINT MANAGEMENT?

For patients with focal DME outside the fovea, we may choose to start with selective laser photo-thermal stimulation. For patients with more advanced disease and diffuse DME, we might choose a combination of anti-VEGF injections with selective laser photo-thermal stimulation. If these treatments are not sufficient, we might inject a steroid delivery device. We may choose a steroid delivery device that lasts for 3 to 5 months or one that lasts for 3 years, depending on the disease severity.

Daniel Lavinsky, MD, PhD, chooses a treatment approach of applying a much larger number of patterned laser treatment sites to increase the area undergoing photo-thermal stimulation (See *Novel Approaches to Laser Therapy to the Macula*, page 6.)

The Synthesis Laser from Topcon Medical Laser systems includes advanced EpM software patterns that facilitate a larger treatment area. The user can now adjust the inner and outer radius around the macula with denser treatment spacing options, allowing the placement of many treatment sites in a macular grid.

At the end of the day, for DME, we will use a combination therapy approach, individualizing treatment to fit disease severity and patients' needs. Having several options available allows us to best treat the disease and serve the patient. ■

Pravin U. Dugel, MD, is Managing Partner of Retinal Consultants of Arizona in Phoenix; Clinical Associate Professor of Ophthalmology, Doheny Eye Institute, Keck School of Medicine at the University of Southern California, Los Angeles;

and Founding Member of the Spectra Eye Institute in Sun City, AZ. He is a member of the Retina Today Editorial Board. Dr. Dugel states that he is a consultant for Alcon, Abbott Medical Optics, ArcticDx, Ora, Regeneron, and ThromboGenics. He can be reached at pdugel@gmail.com.

1. [No authors listed] Photocoagulation for diabetic macular edema. Early Treatment Diabetic Retinopathy Study report number 1. Early Treatment Diabetic Retinopathy Study research group. *Arch Ophthalmol.* 1985;103(12):1796-1806.
 2. Diabetic Retinopathy Clinical Research Network, Elman MJ, Aiello LP, Beck RW, et al. Randomized trial evaluating ranibizumab plus prompt or deferred laser or triamcinolone plus prompt laser for diabetic macular edema. *Ophthalmology.* 2010;117(6):1064-1077.e35. doi: 10.1016/j.ophtha.2010.02.031. Epub 2010 Apr 28.

3. Diabetic Retinopathy Clinical Research Network; Writing Committee, Aiello LP, Beck RW, Bressler NM, et al. Rationale for the diabetic retinopathy clinical research network treatment protocol for center-involved diabetic macular edema. *Ophthalmology.* 2011;118(12):e5-14. doi: 10.1016/j.ophtha.2011.09.058.
 4. Comparison of Age-related Macular Degeneration Treatments Trials (CATT) Research Group; Martin DF, Maguire MG, Fine SL, et al. Ranibizumab and bevacizumab for treatment of neovascular age-related macular degeneration: two-year results. *Ophthalmology.* 2012;119(7):1388-1398. doi: 10.1016/j.ophtha.2012.03.053. Epub 2012 May 1.
 5. Chakravarthy U, Harding SP, Rogers CA, et al. Alternative treatments to inhibit VEGF in age-related choroidal neovascularisation: 2-year findings of the IVAN randomised controlled trial. *Lancet.* 2013. pii: S0140-6736(13)61501-9. doi: 10.1016/S0140-6736(13)61501-1509.
 6. European Medicines Agency. Assessment report: aflibercept. Available at: http://www.ema.europa.eu/docs/en_GB/document_library/EPAR_-_Public_assessment_report/human/002392/WC500135744.pdf.
 7. Enseleit F, Michels S, Ruschitzka F. Anti-VEGF therapies and blood pressure: more than meets the eye. *Curr Hypertens Rep.* 2010;12(1):33-38.

Retinal Laser Therapy Below the Threshold of Visible Damage

The Endpoint Management algorithm provides reliable titration to allow reproducible tissue effects.

By Daniel Palanker, PhD; and Daniel Lavinsky MD, PhD



Retinal photocoagulation is the long-standing standard of care for a wide variety of retinal diseases. The proliferative phase of diabetic retinopathy results from angiogenic factors produced in response to retinal ischemia. Panretinal photocoagulation involves destruction of a significant fraction of the photoreceptors (~30%) in the periphery to limit ischemia and decrease production of angiogenic factors, and thereby spares central vision.

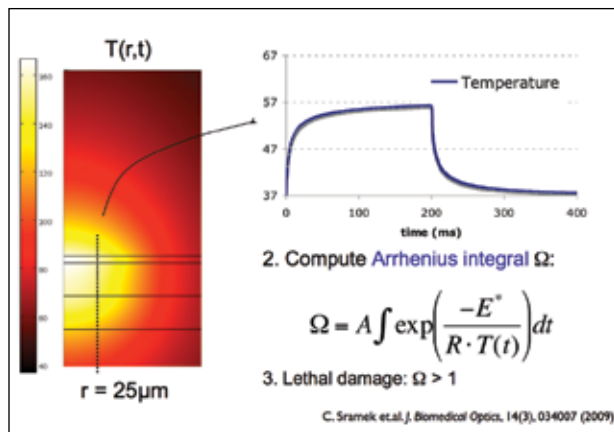


Figure 1. Retinal absorption, heat diffusion and temperature-dependent heat effects in tissue, described by the Arrhenius equation as a rate of chemical reaction.

In laser treatment of macular disorders, including various forms of macular edema, there has been a lack of understanding of treatment mechanisms and associated optimization of treatment settings.

My colleagues and I have studied the dynamics of laser interactions with the retina and built a model to help predict the optimal settings for selective damage to photoreceptors, to retinal pigment epithelium (RPE), and for subdamaging hyperthermia of the retina. This model is based on retinal absorption, heat diffu-

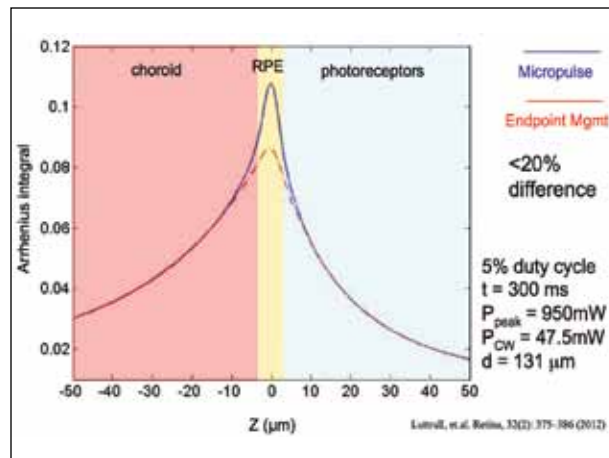


Figure 2. EpM vs micropulse.

sion, and temperature-dependent heat effects in tissue, described by the Arrhenius equation as a rate of chemical reaction (Figure 1). Such quantification of the tissue effects allows optimizing the laser power and duration for the desired endpoint in tissue, relative to laser titration settings for a visible lesion. This is the heart of the algorithm behind the Endpoint Management software (EpM, Topcon Medical Laser Systems). EpM allows producing the desired tissue effects ranging from a barely visible lesion (100%), to minimally traumatic regimen (50%), and non-damaging photo-thermal stimulation (30%). Titration is required because of the variability in pigmentation and transparency of tissue from patient to patient.

DIFFERENTIATING BENEFITS COMPARED WITH MICROPULSE

In my opinion, the most appealing and novel aspect of EpM is that it enables rapid, efficient and reproduc-

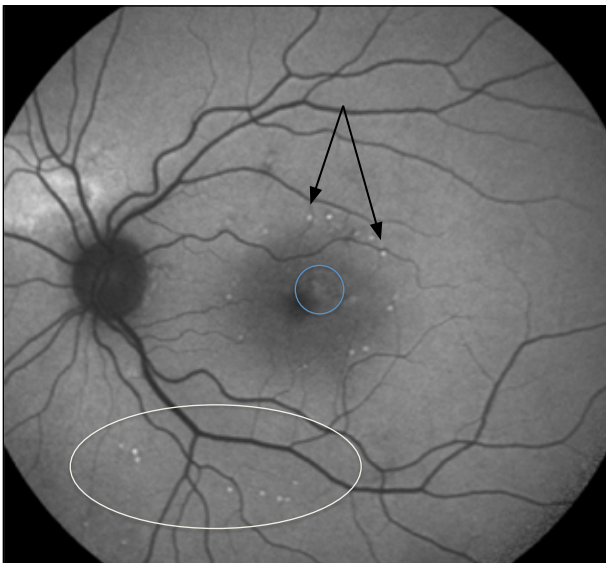


Figure 3. The Landmark feature (arrows) provide physicians with reference markers (set by visible titration—spots in the periphery) on the outer edges of the patterns used for treatment. With Endpoint management, laser energy is delivered at a reduced percentage of the set Landmark power. (Image courtesy of Daniel Lavinsky, MD, PhD.)

The EpM software enables precise control of laser therapy optimized for the desired clinical outcomes, ranging from conventional visible treatment to sub-visible and even non-damaging regimes.

ible treatment below the threshold of tissue damage. Reproducibility is one of the key factors lacking in micropulse laser, due to the absence of an established titration protocol. In addition, long bursts of micropulse laser (200-300 ms) make the application of high density treatment quite long, and not suitable for pattern scanning (Figure 2). Another convenient feature of EpM is its landmark feature, which applies reference markers, set by visual titration, on the outer edges of a selected pattern (Figure 3).

SUMMARY

The EpM software enables precise control of laser therapy optimized for the desired clinical outcomes, ranging from conventional visible treatment to sub-visible and even non-damaging regimes. The EpM algorithm is based on titration to provide predictable and reproducible results in patients with variable absorption and transparency of ocular tissues. ■

Daniel Palanker, PhD, is an Associate Professor in the Department of Ophthalmology at Stanford University School of Medicine and Hansen Experimental Physics Laboratory. Dr. Palanker is a consultant to OptiMedica, Topcon, Medtronic, Oculve, Avalanche Biotechnologies, DigiSight, and Pixium Vision. He may be reached at palanker@stanford.edu.

Daniel Lavinsky, MD, PhD, is with the Department of Ophthalmology, Federal University of Rio Grande do Sul, Porto Alegre, Brazil. Dr. Lavinsky states that he is a consultant to Topcon Medical Laser Systems. He may be reached at daniellavinsky@gmail.com.

Novel Approaches to Laser Therapy to the Macula

Photo-thermal stimulation laser treatment offers many advantages over conventional laser.

By Daniel Lavinsky, MD, PhD



Although laser photocoagulation has been used for decades for the treatment of a variety of retina diseases, there has been no reliable algorithm for parameters that can predict the extent of damage that laser burns will produce. A less-damaging laser therapy, micropulse, was introduced for diabetic macular edema (DME) in 1997 and has been shown to reduce the number of visible laser burns while stimulating tissue for repair. There is no established titration protocol based on an algorithm of laser tissue interaction for micropulse. Therefore, it is difficult to reproduce good results with this technology, particularly among different surgeons. Additionally, with micropulse, it is difficult to tell what areas have been treated when it is time to re-treat.




Figure 1. This graph shows the relationship between energy and pulse duration for the therapeutic window. Above the dotted line is tissue rupture level, and below the dotted line is no tissue effect. The Ω symbols represent the chance of irreversible tissue damage (Arrhenius integral) which correlates to visibility for various methods. The EpM method uses this to maximize the size of the therapeutic window.

EpM works by first titrating to a barely visible level, after which the clinician selects the percentage of energy delivered to the eye below this level.

Endpoint Management (EpM) on the PASCAL Streamline 577 and 532 nm lasers (Topcon Medical Laser Systems) is a method that allows precise control of low-level laser dosages at short durations. EpM works by first titrating to a barely visible level, after which the clinician selects the percentage of energy delivered to the eye below this level (95% to 20%; Figure 1).

MY EXPERIENCE WITH ENDPOINT MANAGEMENT

I participated in the development of EpM while at Stanford University through its experimental phase and have been using the software clinically since October 2012. First, a barely visible titration burn is placed to produce visible landmark reference endpoints. These landmark burns are visible on infrared and are located on the corners of a confluent grid pattern, allowing re-treatment outside the grid or even inside if necessary. The physician then selects the percentage of energy desired, and the parameters are set to reach a phototherapeutic level that produces chemical changes in the retina pigment epithelium (RPE) without damaging any of the cells.

Clinically, and even by optical coherence tomography (OCT; see *Case Report No. 1*), we cannot tell that we are stimulating the cells, but this is apparent in the results. After placing an almost confluent grid of laser onto an eye, the fluid and edema typically decreases over 15 to 40 days.

CASE REPORT NO. 1: CSR

A 32-year-old man diagnosed with chronic central serous retinopathy (CSR) presented with decreased

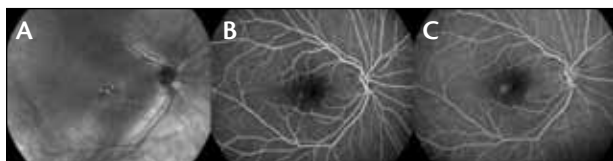


Figure 2. Fluorescein infrared upon presentation (A). FA showed leakage in the foveal area (B, C).



Figure 3. The area that was treated with photo-thermal stimulation on FA (A) and OCT (B).



Figure 4. One month after treatment with photo-thermal stimulation, there were no visible laser burns on FA (A) and no visible damage on OCT (B).

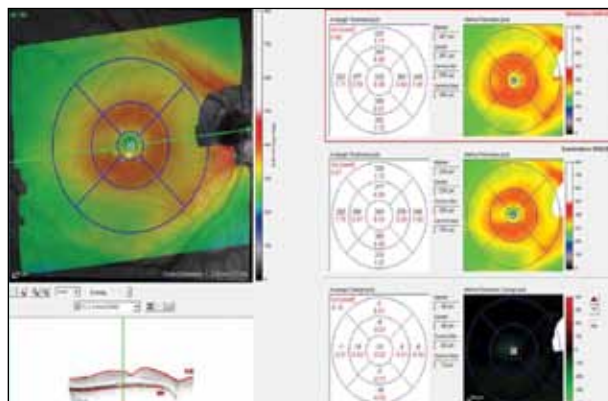


Figure 5. Retinal thickness map comparing the thickness before and after photo-thermal stimulation.

visual acuity of 20/60 that had persisted for more than 4 months. Figure 2A shows the infrared fluorescein images of the patient upon presentation. For a case of acute CSR I usually observe, but in cases of chronic CSR I treat with either medications or laser. The patient declined treatment with steroids, as oral or topical steroids can sometimes cause CSR. Figures 2B and C show leakage into the foveal area on fluorescein, which cannot be treated with conventional laser. My choices for this patient were photodynamic therapy, micropulse laser, or photo-thermal stimulation with EpM on the PASCAL laser. I chose to treat the patient with photo-thermal stimulation.

My parameters for EpM are a 200 μm spot size and 100% of 120 mW for the titration burn. I lowered the EpM energy setting to 30% and used a confluent grid with 0.25 spot diameter distance between each spot. The landmarks were turned off in this case because I did not want to have visible reference points in the area that I was treating. I placed 368 spots of laser over this area, seen on fluorescein angiography (FA) and OCT in Figure 3.

After 1 month there was complete resolution of the subretinal fluid with no visible laser burns on FA and no visible damage on OCT (Figure 4). With conventional photocoagulation, one would expect to see visible damage, which is easily discerned on OCT. The vision was 20/20 in both eyes at 1 month.

Figure 5 shows the retinal thickness map comparing the thickness before and after photo-thermal stimulation. Although the difference is not drastic, the thickness is completely normal, having decreased by 82 μm after laser.

CASE REPORT NO. 2: CSR

A 61-year-old woman presented with chronic CSR and visual acuity of 20/60 in her left eye that had persisted

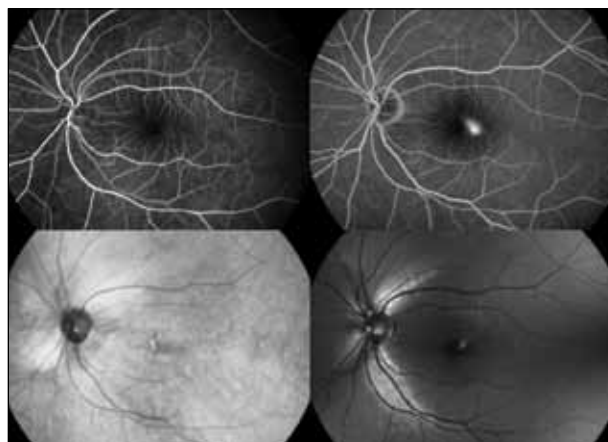


Figure 6. Fluorescein angiography of the patient's left eye.

for 6 months (Figure 6). She did not receive any steroids or other systemic medications. I treated the patient with EpM photo-thermal stimulation. Figure 7A shows central macular thickness (CMT) of 336 μm .

I used a 200 μm spot size and 120 mW at 100% for the test burn, lowering energy to 30% for the treatment. The laser spots were placed in a confluent grid 0.25 spot diameters apart. I had the landmarks set to "on" and placed 520 spots.

One month post-laser, the patient's vision had improved to 20/30 (Figure 7B). At 5-month follow-up, vision was 20/25 and CMT had decreased to 225 μm (Figure 7C). Because there was residual

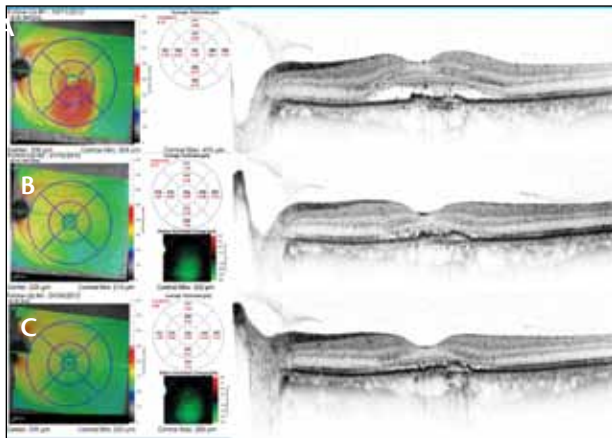


Figure 7. The patient's CMT at baseline was 336 μm (A) and visual acuity was 20/40; at 1-month follow-up the CMT had decreased to 225 μm (B) and visual acuity was 20/30; and at 5-month follow-up CMT had decreased to 236 μm (C) and visual acuity was 20/25.

subretinal fluid at 5 months, we decided to re-treat at this time. At final follow-up, 8 months after EpM treatment, the patient's vision had improved to 20/20 and the CMT had decreased to 181 μm (Figure 8).

CASE NO. 3: DME

A 47-year old woman presented with a 12-year history of type 2 diabetes. She had diffuse DME and best corrected visual acuity of 20/80 in both eyes (Figure 9). I treated the patient with laser using EpM. I used a 200 μm spot size and 120 mW at 100% for the test burn, lowering energy to 30% for the treatment. The laser spots were placed in a confluent grid 0.25 spot diameters apart. I had the landmarks set to "on" and placed 693 spots.

At 6 months post laser, the patient's visual acuity had improved to 20/25 (Figure 10), and the patient required no anti-VEGF injections.

SUMMARY

In general, I have found that my patients respond well to the photo-thermal stimulation that EpM provides. I no longer use conventional laser in any disease

For more information on PASCAL lasers and Endpoint Management, visit www.tmlsinc.com.

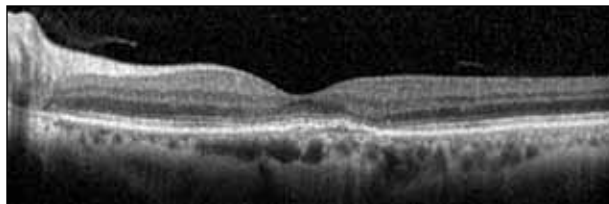


Figure 8. At final follow-up, 7 months after treatment with photo-thermal stimulation, CMT was 181 μm and vision was 20/20.

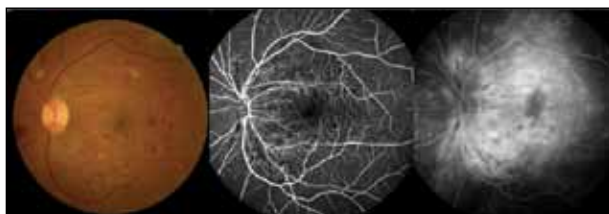

Figure 9. Diffuse DME. The patient's baseline visual acuity was 20/80.

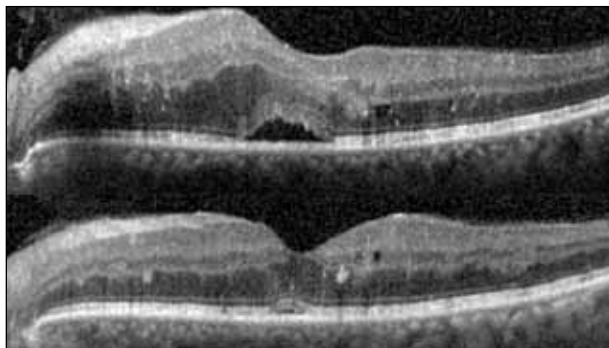


Figure 10. Six months post-laser, the patient's visual acuity improved to 20/25 and no anti-VEGF injections were required.

that lies close to the posterior pole. I am more likely to treat chronic CSR and DME earlier with photo-thermal stimulation using EpM because I no longer worry about inducing damage to the tissue. ■

Daniel Lavinsky, MD, PhD, is with the Department of Ophthalmology, Federal University of Rio Grande do Sul, Porto Alegre, Brazil. Dr. Lavinsky states that he is a consultant to Topcon Medical Laser Systems. He may be reached at daniellavinsky@gmail.com.

Patient cases are for informational purposes only and do not purport any treatment instructions for use by Topcon Medical Laser Systems, Inc.